

## Laparoscopic Resection of Large Endo-Cervical Polyp Through Posterior Colpotomy as an Alternative Access to Vagina in Virgin Patients

Maha Al Baalharith and Saeed Alsary\*

King Abdulaziz Medical City, National Guard Health Affairs, Riyadh, Saudi Arabia

### \*Corresponding author:

Saeed Alsary,  
National guard health affairs, king Abdulaziz  
medical city, P.O. Box 22490 Riyadh 11426,  
Saudi Arabia, E-mail: alsarysaeed@gmail.com

Received: 08 Dec 2021

Accepted: 28 Dec 2021

Published: 03 Jan 2022

J Short Name: ACMCR

### Copyright:

©2021 Saeed Alsary. This is an open access article distributed under the terms of the Creative Commons Attribution License, which permits unrestricted use, distribution, and build upon your work non-commercially.

### Citation:

Saeed Alsary, Laparoscopic Resection of Large Endo-Cervical Polyp Through Posterior Colpotomy as an Alternative Access to Vagina in Virgin Patients. Ann Clin Med Case Rep. 2022; V8(5): 1-4

### Keywords:

Colpotomy; Hymen; Laparoscopy; Leiomyoma; Polyp

### 1. Abstract

Endometrial polyps have been involved in about 50% of patients with abnormal uterine bleeding and 35% of infertile patients. Management of pedunculated endocervical myoma or polyp normally requires intervention via the vaginal route. Laparoscopy provides safe alternative in patients demanding hymenal integrity. A 28-year-old, nulliparous virgin woman who presented with anemia secondary to heavy menstrual bleeding for five years. Pelvic ultrasound and MRI showed a 3.2 x 2.4 cm mass at the upper vagina it concluded that the mass likely to be pedunculated uterine fibroid, other differential diagnosis including endometrial polyp. Due to the patient's consistent desire for preserving hymenal integrity, laparoscopic posterior colpotomy was performed and the mass was removed successfully.

### 2. Introduction

Endometrial polyp is an overgrowth of endometrial glands, stroma and blood vessels. risk factors for endometrial polyps include advanced age, high body mass index, systemic hypertension, diabetes mellitus, nulliparity, late menopause, estrogen replacement therapy, and tamoxifen treatment [1,2]. It is commonly benign lesions in nature and vary in size which might occupy a space into the endometrial cavity [3]. Patients might either present at their reproductive age or post-menopause [1]. Endometrial polyp is fairly common, patients may present with abnormal uterine bleeding. The primary tool for initial diagnosis of endometrial polyps is transvaginal ultrasonography. Endometrial polyps appear as a hyperechogenic lesion with regular contours [4]. In asymptomatic women, endometrial polyps may subside spontaneously, but <http://acmcaseports.com>

symptomatic women with endometrial polyps often treated by resection either vaginally as in most cases or abdominally in few other cases. Abdominal route for polypectomy is solely driven by patient demand. Endometrial polyps have been involved in about 50% of patients with abnormal uterine bleeding [5] and 35% of infertile patients [6]. In some societies, Virginity is defined as the integrity of the hymen, as it is considered a sign of sexual purity and for that, an intact hymen considered major social concerns for the patient herself and her family [7]. Vaginal approach for surgical procedures in patients with intact hymen comes with major concerns for both patient and her family [7].

The diagnosis, evaluation and treatment of prolapsed pedunculated submucous leiomyoma may need vaginal access which may affect the hymenal integrity [8]. In 2016, Wehbe et al. stated that Laparoscopic management of a pedunculated myoma provides good access and he described its safety as a management tool by a skilled laparoscopic gynaecologic surgeon [8]. Up to our knowledge, there are only two reported cases with a similar scenario to our case worldwide. This is the first reported case from Saudi Arabia. Laparoscopic resection of pedunculated endometrial polyp/myoma into the vagina can be offered as management option in a patient who seek virginity preservation with experienced surgeon.

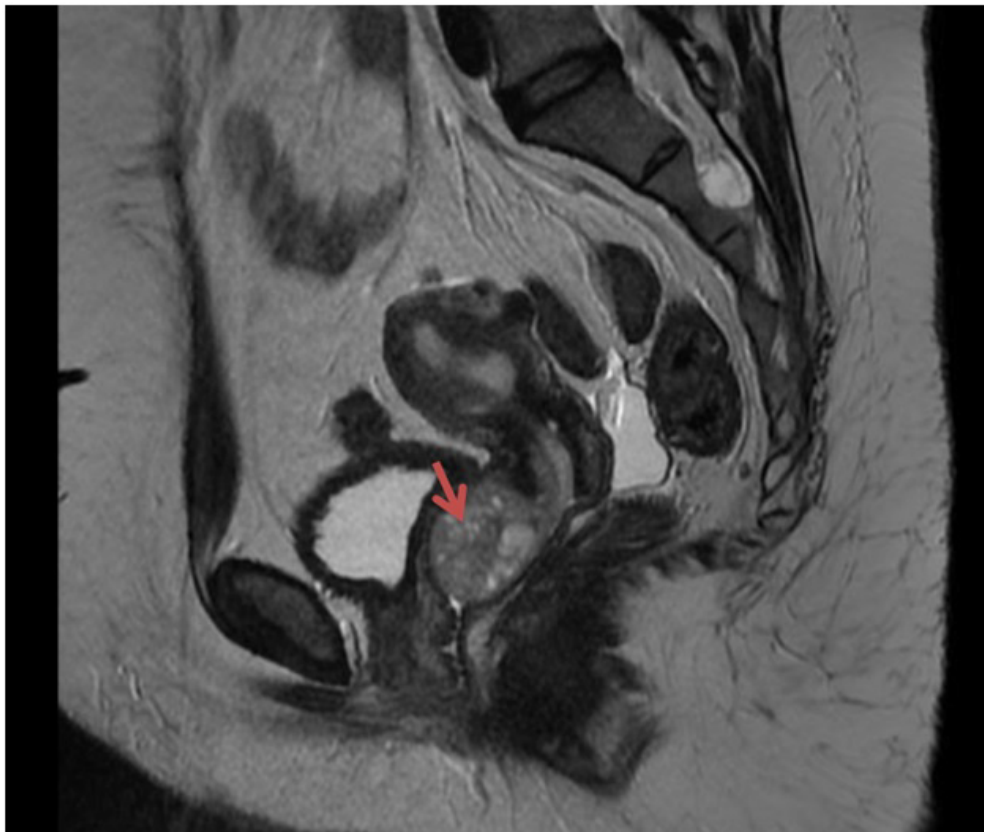
### 3. The Case

28 years old single (never been in sexual relationship) was referred by her hematologist to our clinic as a case of anemia secondary to heavy menstrual bleeding for five years. Her condition got worse over the past 12 months prior to her presentation to our clinic. She has been treated with iron infusion every other month. Her Medi-

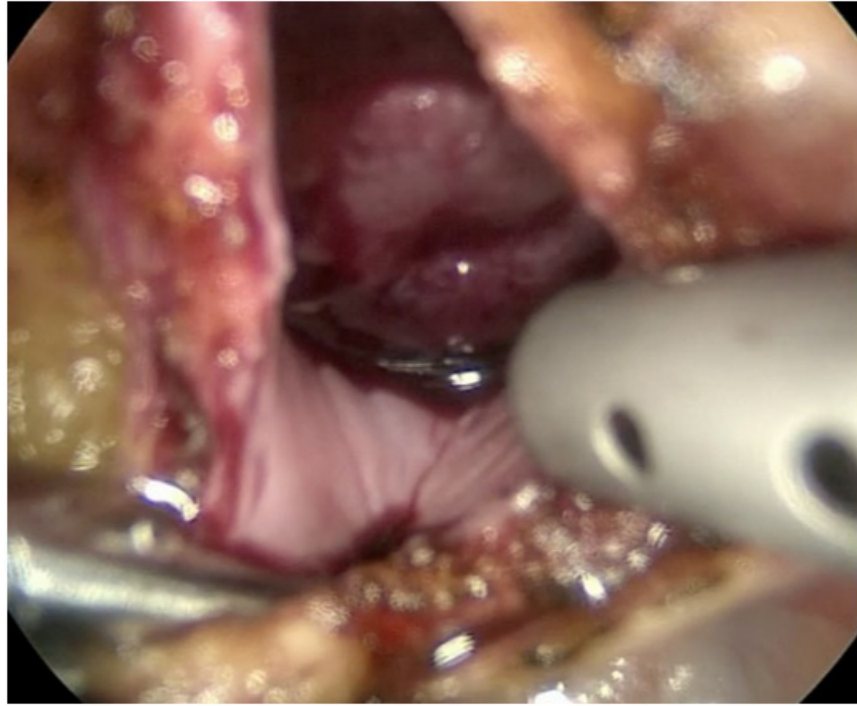
cal and surgical history was otherwise unremarkable. The patient weight was 83 kg, height 149 cm, BMI 37.39kg/m<sup>2</sup>. Generally she looked tired, pale with stable vital signs. Her abdomen was soft, non tender, no palpable masses. As the patient was vergin, vaginal exam was not done but yet normal external genitalia. She was investigated with pelvic ultrasound which concluded that there is a heterogenous mass seen at the end of cervix going to the vagina size: 3 x 1.8 x 2.7cm with a large vessel comes from the uterine cavity supplying the mass. Pelvic MRI then was done and it showed a 2.8 X 3cm upper vaginal mass mostly cervical polyp pedunculated to the vagina. Partial septate uterus with 2cm superior septum. Patient initially opted conservative management. She continued to have heavier menstrual cycles. Pelvic MRI then was repeated one year later and it showed a 3.2 x 2.4 cm upper vagina mass likely pedunculated uterine fibroid, other differential diagnosis including endometrial polyp with a partially septate uterus. It showed as well few small uterine fibroids (sub-serosal) and other intramural at the fundal area and at the posterior uterine wall (Figure 1). Patient was counseled for vaginal approach through hysteroscopy with resection of pedunculated endometrial polyp with possibility of injuring the hymen. She strongly asked for another surgical approach if possible otherwise she will not go for surgery. Patient was proposed to have her surgery via laparoscopy as an alternative option for the usual vaginal route. She showed happiness and gratitude. Patient was prepared for laparoscopic resection of her polyp via posterior vaginal colpotomy. Laparoscopy was performed in the usual fashion for pelvic surgery with scop

inserted through umbilical port 10mm. Three ancillary ports at the lower abdomen each 5mm. Intraoperatively revealed three small subserosal fibroids as seen by MRI preoperatively which were all resected successfully. Then the uterus was suspended to the abdominal wall using one of the stiches used to close the myomectomy site of the uterine wall. The thread was retrieved using endo closure device in order to improve the operative site visibility at the pouch of Douglas. Posterior colpotomy (about 3cm in diameter) between the two uterosacral ligaments in a horizontal fashion was performed using monopolar Hook. Exposurue of the vaginal leumen was achieved and eventually the large pedunculated polyp was visualised (Figure 2). It was grasped and pulled towards the pelvic cavity. The pedicle was identified coming from the endocervix. It was coagulated with bipolar forceps then it was cut (Figure 3).

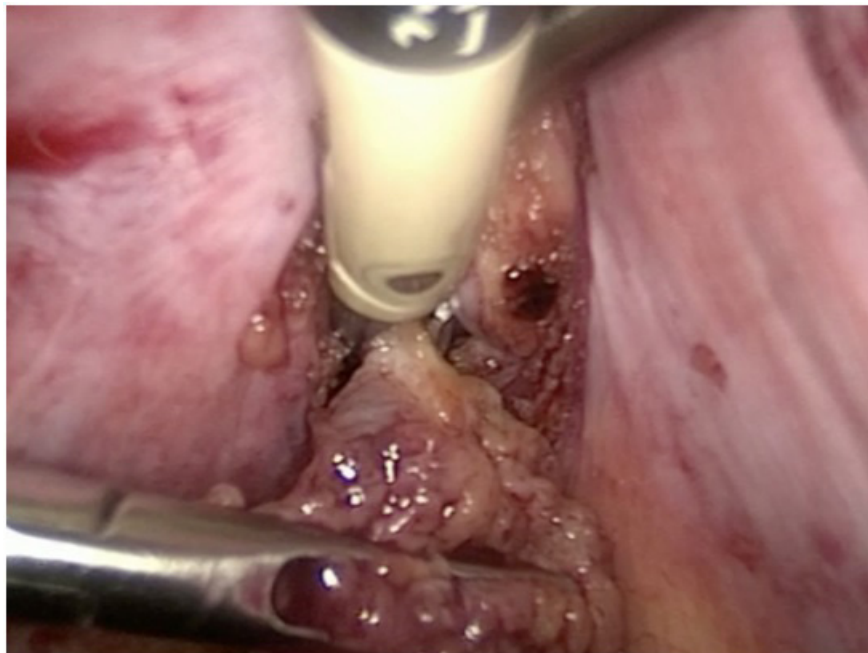
Finally the excised polyp was extracted through an endopag and sent for histopathology. Vaginal incision was then closed with 2-0 V-Lock absorbable suture in a continous fashion (Figure 4). Surgery was smooth with no complications and minimal blood loss. Patient was discharged home on day one post operatively in a good condition. The final histopathology report came back as uterine leiomyomata for the resected uterine fibroids and simple endometrial polyp for the vaginal mass. Patient was given a follow up appointment in our clinic two weeks after discharge. Histopathology result was discussed with the patient and over three months post operatively she reported a normal menstrual cycle.



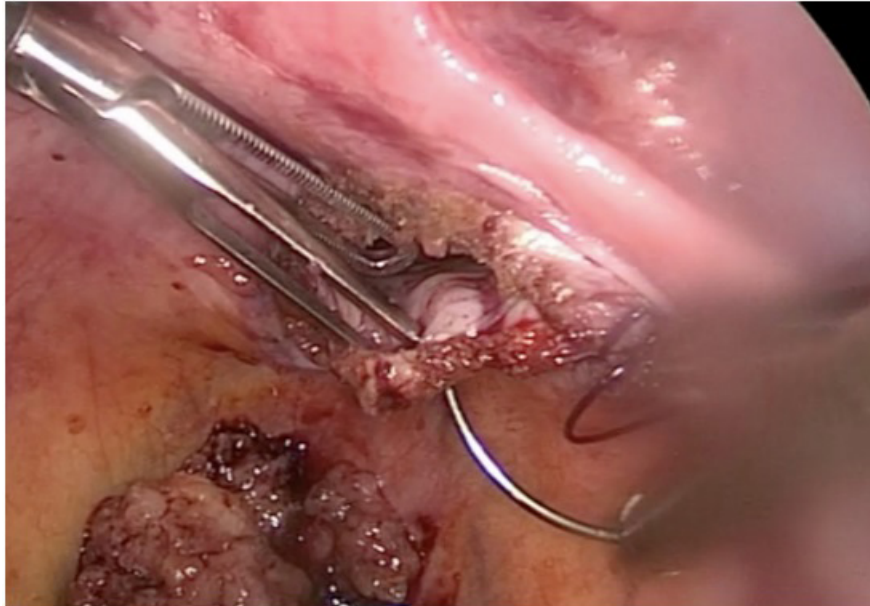
**Figure 1:** Pelvic MRI showing endocervical polyp occupying the upper vagina.



**Figure 2:** Colpotomy and visualization of the endo cervical polyp.



**Figure 3:** Coagulation and cutting of the pedicle of endocervical polyp.



**Figure 4:** Colpotomy closure using V-Lock absorbable 2-0 stitches.

#### 4. Discussion

Endometrial polyp has a major concern for most of women complaining of abnormal uterine bleeding (AUB), infertility, and recurrent pregnancy losses. It is evident that virginity preservation, which is defined as an intact hymen, is vital and essential in many societies and cultures with a religious background. Most of our patients and their families decline and fear the idea of a vaginal approach procedure that might affect the integrity of the hymen in single females. Hymenal injury, in the patient's perspective losing virginity after surgical interventions, might affect her psychologically and put her under a lot of stressors and social burden, so the surgeon should be able to give the patient another alternatives and options that will provide the best care and most importantly least invasive. We believe that women should be supported whatever their choices are.

#### References

1. Reslova T. "Endometrial Polyps. A Clinical Study of 245 Cases." *Archives of Gynecology and Obstetrics*. 2019; 262: 3-4.
2. Nijkang N P, Anderson L, Markham R, Manconi F. Endometrial polyps: Pathogenesis, sequelae and treatment. *SAGE Open Medicine*. 2019.
3. Chaudhry, Sidhartha. "Benign and Malignant Diseases of the Endometrium." *Topics in Magnetic Resonance Imaging*. 2003.
4. La Torre R. "Transvaginal Sonographic Evaluation of Endometrial Polyps: A Comparison with Two Dimensional and Three Dimensional Contrast Sonography." *Clinical and Experimental Obstetrics & Gynecology*, vol. 1999.
5. Tjarks M. "Treatment of Endometrial Polyps." *Obstetrics & Gynecology*, vol. 96, no. 6, Dec. 2000; 886-889.
6. Check JH. "Matched Controlled Study to Evaluate the Effect of Endometrial Polyps on Pregnancy and Implantation Rates Following in

Vitro Fertilization-Embryo Transfer (IVF-ET)." *Clinical and Experimental Obstetrics & Gynecology*. 206-208.

7. Yalçın I, Mini-laparotomic Colpotomy for a Cervicovaginal Leiomyoma: Preservation of hymenal integrity. *IJRM*. 2016; 14(3): 217-20.
8. GS Wehbe. Laparoscopic posterior Colpotomy for a Cervico-vaginal Leiomyoma: hymen conservative technique. *FVVO*. 2016; 8 (3): 169-181.