

## Dermatomyositis Revealing Poorly Differentiated Neuroendocrine Carcinoma of the Gallbladder: A Case Report and Review of the Literature

Feki J<sup>1</sup>, Guermazi Z<sup>1</sup>, Frikha F<sup>2\*</sup>, Jlidi R<sup>3</sup>, Bahloul Z<sup>2</sup> and Khanfir A<sup>1</sup>

<sup>1</sup>Department of oncology, Habib Bourguiba university Hospital, Sfax, Tunisia

<sup>2</sup>Department of Internal Medicine Hédi Chaker university Hospital, Sfax, Tunisia

<sup>3</sup>Pathologist free practice, Sfax, Tunisia

### \*Corresponding author:

Faten Frikha,  
Department of Internal Medicine Hédi  
Chaker university Hospital, Sfax,  
Tunisia, E-mail: fetenfrikha@yahoo.fr

Received: 21 July 2021

Accepted: 05 Aug 2021

Published: 11 Aug 2021

### Copyright:

©2021 Frikha F. This is an open access article distributed under the terms of the Creative Commons Attribution License, which permits unrestricted use, distribution, and build upon your work non-commercially.

### Citation:

Frikha F, Dermatomyositis Revealing Poorly Differentiated Neuroendocrine Carcinoma of the Gallbladder: A Case Report and Review of the Literature. Ann Clin Med Case Rep. 2021; V7(4): 1-4

### Keywords:

Neuroendocrine Carcinoma; Gallbladder;  
Dermatomyositis

## 1. Abstract

**1.1. Objective:** To contribute to the increased understanding of the clinical features of neuroendocrine carcinoma of the gallbladder revealed by a dermatomyositis.

**1.2. Clinical presentation:** We report the case of a 50-year-old man with neuroendocrine carcinoma of the gallbladder revealed by dermatomyositis. He was hospitalized with myalgia muscular weakness in four limbs. He had so concomitant pain in the right upper quadrant. Cutaneous examination revealed palpebral edema with a predominant redness on the lower eyelids and periungual painful erythema. Computed tomography showed multiple metastatic liver nodules, suspicious irregular thickening of the bottom of the gallbladder, associated with multiple retro peritoneal lymph nodes. Histopathological study showed neoplastic infiltration by small and large cells with an endocrine type arrangement. A high dose corticosteroid was instituted. After ten days, the patient presented a clear improvement of muscle and skin symptoms. Palliative chemotherapy by etoposide and cisplatin was introduced. The patient died after 3 cycles.

**1.3. Discussion:** Few cases of neuroendocrine tumors of gallbladder have been reported in the literature. This highly malignant tumor is often discovered at a late stage. His prognosis remains poor. The therapeutic management is not well codified given the rarity of this entity. The multimodal treatment with surgical resection, radiotherapy and chemotherapy may help increase survival of patients.

<http://acmcase reports.com/>

**1.4. Conclusion:** The neuroendocrine carcinoma of the gallbladder should be added to the list of malignancies with dermatomyositis and has to be excluded by relevant investigation, especially since an inexpensive, simple and easily available initial testing exists (abdomen sonography).

## 2. Introduction

Neuroendocrine tumors (NET) represent 1.25% of all malignant tumors [1]. The majority of them occur in the gastrointestinal tract (66%), followed by the bronchopulmonary system (31%). Less frequently NETs can affect the ovaries, testes, pancreas [1]. NET of the extrahepatic duct and gallbladder (GB) only are very rare, account for 0.2% of all gastrointestinal tract NETs [1-5].

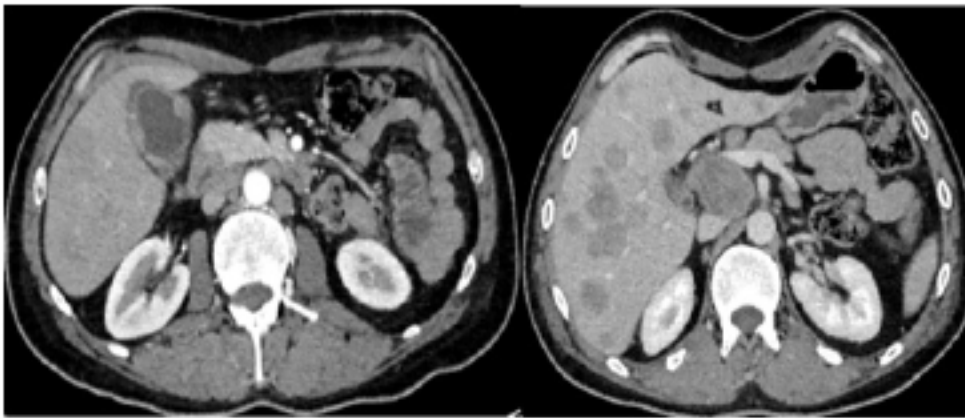
NETs of the GB include well-differentiated NETs grade 1 and 2, neuroendocrine carcinoma (NEC) with small or large cell and mixed carcinoma adeno-neuroendocrine [3]. Only 73 cases of small cell NEC and 10 cases of large cell NEC of GB have been reported in the literature up to now [3]. The NEC with large cell of the GB is extremely rare, characterized by its more aggressive behavior [6]. Here we report a case of poorly differentiated neuroendocrine carcinoma with large and small cells of the GB in a 50-year-old man, revealed by dermatomyositis.

## 3. Observation

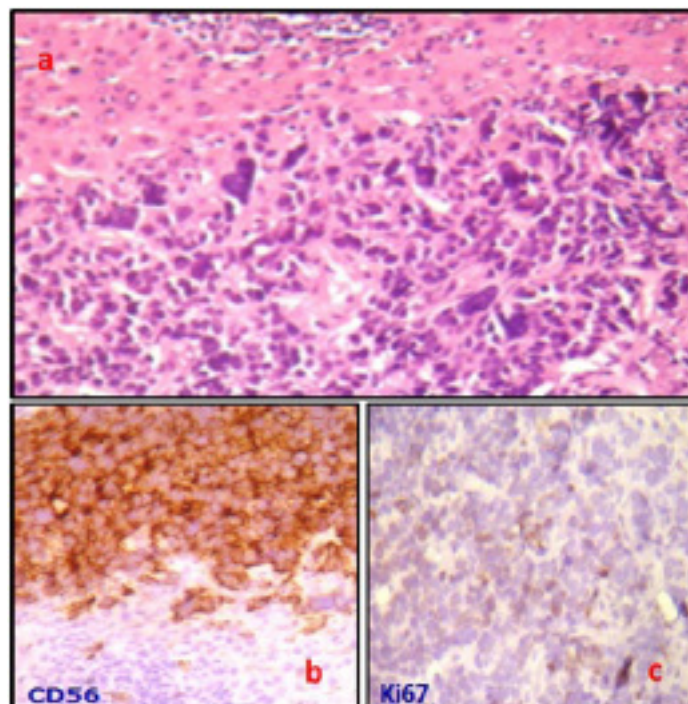
A 50-year-old man with no particular history was hospitalized with myalgia muscular weakness in four limbs that began 3 months prior associated with deterioration in general health with asthenia and

weight loss of 10 kg. He had so concomitant pain in the right upper quadrant. Physical examination revealed bilateral and symmetrical muscle weakness of scapular and pelvic girdles side to 3/5 with sign of the stool. There was a swallowing disorder. Cutaneous examination revealed palpebral edema with a predominant redness on the lower eyelids and periungual painful erythema. There was abdominal sensation in right upper Quadrant. The lymph nodes were free and the rest of the examination was normal. Laboratory tests found AST 162 IU / L, ALT 95 IU / L, CPK to 310 IU / L (N <150 U / L) and cholestasis: gamma glutamyl transferase to 447 IU / L (N: 5 -36), alkaline phosphatase to 341 IU / L (N: 35-105). The electromyogram highlighted a myogenic syndrome of four members. Computed tomography (CT) showed multiple

metastatic liver nodules, suspicious irregular thickening of the bottom of the gallbladder 2.3 X 2.5 cm, arriving in contact with the right angle colic with loss of greasy security border associated with multiple retro peritoneal lymph nodes whose bulkier was 5.7 X 3 cm in size, no lesions on the thoracic level (Figure 1). Histopathological study showed neoplastic infiltration by small and large cells with an endocrine type arrangement: cells arranged in clusters, in bays or rosettes. Neoplastic cells fairly uniform had a reduced cytoplasm in small cells and quite abundant in the large cells (<40%), tumor cells showed some multi nucleation and nuclear monstrosities. Mitosis were numerous (> 15 mitoses per ten fields). Tumor cells were positive for synaptophysin and anti-CD56 with a proliferative index (Ki67)> 50% (Figure 2).



**Figure 1:** Computed tomography (CT) showed multiple metastatic liver nodules, tumor thickening of the gallbladder: irregular thickening of the bottom of the gallbladder 2.3 X 2.5 cm, arriving in contact with the right angle colic with loss of greasy security border associated with multiple retro peritoneal lymph nodes whose bulkier was 5.7 X 3 cm in size, no lesions on the thoracic level



**Figure 2:** a : Histopathological study : neoplastic infiltration by small and large cells with an endocrine type arrangement b : Positivité des cellules tumorales pour le CD56; c : Tumor cells were positive for CD56; b : Tumor cells were positive for Ki67 with a proliferative index (Ki67)> 50%.

A bone scan performed in the staging objectified two suspicious hyperfixations of the 3rd and the 12th left rib. Diagnosis of poorly differentiated neuroendocrine carcinoma with small and large cells of the gallbladder with liver and bone metastases, revealed by paraneoplastic dermatomyositis was retained. Faced with this DM with initial signs of severity, a corticosteroid therapy was instituted, including pulse methylprednisolone 1 g / day for three days with relay by oral corticosteroids prednisone at high doses. After ten days of high dose corticosteroid, the patient presented a clear improvement of muscle and skin symptoms. Palliative chemotherapy by etoposide and cisplatin was introduced. The patient died after 3 cycles of chemotherapy.

#### 4. Discussion

Neuroendocrine tumors (NET) of GB are rare representing only 0.5% of all NET and less than 1% of tumors of the biliary tract [7]. The first case was published in 1929. Their etiopathogeny remains unclear. Neuroendocrine cells are distributed throughout the gastrointestinal tract, the bronchi, endocrine glands and skin. The gallbladder mucosa is devoid of neuroendocrine cells, which can appear after intestinal metaplasia due to chronic inflammation. This fact explains why NENs rarely occur in the gallbladder. Virtually all published reports on gallbladder NENs describe coexisting gallstones and chronic cholecystitis [1,7, 8,9].

According to the 2010 World Health Organization (WHO) classification, NETs are classified into four categories, that are mainly based on mitotic count and the Ki67 proliferation index: (1) well differentiated NET or grade 1 tumor, with a mitotic count of <2/10 per high-power fields (HPF) and a Ki67 of  $\leq 2\%$ , such as a typical carcinoids; (2) intermediate differentiated NET or grade 2 tumor, with a mitotic count of between 2 and 20/ 10 HPF and a Ki67 of 3% to 20%, such as an atypical carcinoids; (3) poorly differentiated NEC or grade 3 tumor, with a mitotic count of >20/10 HPF and a Ki67 of >20%, which includes small-cell and large-cell NECs; and (4) mixed adenoneuroendocrine carcinoma, histologically exhibiting concomitant adenocarcinoma (or other components) and NEC concomitantly [1,3].

The tumor described in this observation meets the diagnostic criteria for poorly differentiated endocrine carcinoma with small and large cell: an evocative architecture tumor of endocrine differentiation with organoid arrangement of cells in the lobules, in bays, fences or rosettes; large and small cell size; the presence of tumor necrosis areas; the expression of at least one neuroendocrine markers (synaptophysin and CD56), a mitotic index over 15 mitosis in ten fields with a proliferative index (Ki67) > 50%.

Clinically, NECs are often revealed by a tumoral syndrome with non-specific symptoms (intermittent pain in the right upper quad-

rant, jaundice...) and a deterioration in general condition [10]. In this location, it has not been described in functional clinical syndrome for these high-grade malignant tumors, whether with small or large cell; but sometimes a paraneoplastic syndrome. Indeed, in our case, the tumor was revealed by symptoms suggestive of paraneoplastic dermatomyositis (DM) which according to the literature may be associated with cancer in 14% of cases. The DM may appear before cancer, at the same time as cancer or after cancer diagnosis [11, 12].

His etiopathogeny is unclear. It is associated in order of frequency with a breast, lung, ovarian, stomach, colon, uterus and nasopharynx cancers. The association of DM and cancer of the GB has rarely been described in the literature [11]. To our knowledge we report the observation of a seventh DM associated with carcinoma of the GB. The treatment of DM is empirical, often involving a combination of corticosteroids and immunosuppressive drugs [13]. The cancer treatment may also lead to the resolution of the DM [11].

Poorly differentiated neuroendocrine carcinoma with large cell of the GB are high-grade malignant tumors and metastatic immediately in a third of cases [10]. These highly malignant tumors progressing rapidly with early lymphatic involvement and frequent liver metastases [2,10].

Surgical resection is considered the primary treatment of NEC of GB, can expect improved patient prognosis [14]. However, surgery is not always possible because the tumor is often discovered at a late stage. Thus, chemotherapy occupies a prominent place in the management of the NEC of GB locally advanced or metastatic. The cisplatin and etoposide is the most commonly used first line. Instead of radiation therapy has not been well established given the rarity of this entity. In our patient, the NEC was diagnosed with inoperable metastatic stage indicating systemic treatment with chemotherapy.

The prognosis is unfortunate with a median overall survival of around 4 to 6 months despite aggressive treatment [3].

#### 5. Conclusion

The NEC of the GB is a very rare tumor characterized by a high potential for malignancy and late diagnosis of the disease. It should be added to the list of malignancies with dermatomyositis and has to be excluded by relevant investigation, especially since an inexpensive, simple and easily available initial testing exists (abdomen sonography). His prognosis is poorer than that of adenocarcinoma of the GB. The therapeutic management is not well codified given the rarity of this entity. The multimodal treatment with surgical resection, radiotherapy and chemotherapy may help increase survival of patients.

## References

1. Liu W, Wang L, He X, Feng C, Chang X, Lu Z. Mixed large cell neuroendocrine carcinoma and adenocarcinoma of the gallbladder: a case report and brief review of the literature. *World J. Surg. Oncol.* 2015; 13: 114.
2. Chen C, Wang L, Liu X, Zhang G, Zhao Y, Geng Z. Gallbladder neuroendocrine carcinoma: report of 10 cases and comparison of clinicopathologic features with gallbladder adenocarcinoma. *Int J ClinExp Pathol* 2015; 8: 8218-26.
3. Kamboj M, Gandhi JS, Gupta G, Sharma A, Pasricha, Mehta A, et al. Neuroendocrine Carcinoma of Gall Bladder: A Series of 19 Cases with Review of Literature. *J Gastrointest Cancer.* 2015; 46: 356-64.
4. Albores-Saavedra J, Henson DE, Angeles AA. Tumors of the Gall-bladder and Extrahepatic Bile Ducts. *Atlas of Tumor Pathology. Third series.* Washington D.C, AFIP. 2000.
5. Demoreuil C, Thirot-Bidault A, Dagher C, Bou-Farah R, Benbrahim C, Lazure T, et al. Carcinome endocrine peu différencié à grandes cellules des voies biliaires extrahépatiques. *Gastroentérologie Clinique et Biologique.* 2009; 33: 194-18.
6. Okuyama Y, Fukui A, Enoki Y, Morishita H, Yoshida N, Fujimoto S. A large cell neuroendocrine carcinoma of the gall bladder: diagnosis with 18 FDG-PET/CT-guided biliary cytology and treatment with combined chemotherapy achieved a long-term stable condition. *Jpn J Clin Oncol.* 2013; 43: 571-4.
7. Eltawil KM, Gustafsson BI, Kidd M, Modlin IM. Neuroendocrine tumors of the gallbladder: an evaluation and reassessment of management strategy. *J Clin Gastroenterol.* 2010; 44: 687-95.
8. Silvia M, Vincezo P, Orazio S, La Torre V, Cimadon B, Leopizzi M, et al. Neuroendocrine tumors of the gallbladder: a case report and review of the literature. *Journal of Medical Case Reports.* 2015; 5: 334.
9. Zuetenhorst JM, Taal BG. Metastatic carcinoid tumors: a clinical review. *Oncologist.* 2005; 10: 123-31.
10. Faggiano A, Sabourin J.C, Ducreux M, Lumbroso J, Duvillard P, Leboulleux S, et al. Pulmonary and extrapulmonary poorly differentiated large cell neuroendocrine carcinomas. Diagnostic and prognostic features *Cancer.* 2007; 110: 265-74.
11. Jurcic P. Dermatomyositis as the first manifestation of gallbladder adenocarcinoma: case report and literature overview. *World J Surg Oncol.* 2015; 13: 127.
12. Zhang W, Jiang SP, Huang L. Dermatomyositis and malignancy: a retrospective study of 115 cases. *Eur Rev Med Pharmacol Sci.* 2009; 13: 77-80.
13. Wolff K, Johnson R. Fitzpatrick's color atlas and synopsis of clinical dermatology. 6. New York: McGraw-Hill. 2009.
14. Moskal TL, Zhang PJ, Nava HR. Small cell carcinoma of the gallbladder. *J Surg Oncol.* 1999; 70: 54-9.