

Early Cervical Cancer Recurred with Uterine Fundus Metastasis After Laparoscopic Fertility-Sparing Surgery: A Case Report

Shen Y^{1,*}, Wan X¹, Liu J² and Xie X¹

¹Department of Gynecologic Oncology, Women's Hospital, School of Medicine, Zhejiang University, Hangzhou 310006, China

²Sun Yat-sen University Cancer Center, Guangzhou, Guangdong 510060, China

*Corresponding author:

Yuanming Shen,
Department of Gynecologic Oncology,
Women's Hospital, School of Medicine,
Zhejiang University,
Hangzhou 310006, China,
E-mail: 13588193832@163.com

Received: 07 Oct 2020

Accepted: 23 Oct 2020

Published: 28 Oct 2020

Copyright:

©2020 Shen Y. This is an open access article distributed under the terms of the Creative Commons Attribution License, which permits unrestricted use, distribution, and build upon your work non-commercially.

Citation:

Shen Y, Early Cervical Cancer Recurred with Uterine Fundus Metastasis After Laparoscopic Fertility-Sparing Surgery: A Case Report. *Annals of Clinical and Medical Case Reports*. 2020; 5(1): 1-5.

#Author Contributions:

Shen Y, Wan X, Liu J and Xie X, These authors have contributed equally to this article.

Keywords:

Cervical squamous cell carcinoma; Fertility-sparing surgery; Radical trachelectomy

1. Abstract

Recently, the safety of minimally invasive radical hysterectomy for cervical cancer caused widespread controversy. However, the safety of minimally invasive fertility-sparing surgery for early stage cervical cancer is still uncertain. Here we reported a special uterine fundus implanted recurrent case who was diagnosed as stage IB2 (FIGO2012) squamous cell cervical carcinoma and undergone neoadjuvant chemotherapy plus laparoscopic radical trachelectomy (NCT02624531) because of strongly desiring to preserve the fertility. This firstly reported case with special metastatic manner indicates that the safety of laparoscopic radical trachelectomy is still uncertain for advanced stage cervical cancer even if neoadjuvant and post-surgery chemotherapy is given, and also suggests that it is needed to discuss carefully the benefit and risk of such a strategy with the patient when the fertility preservation is considered.

2. Abbreviations: SCC Ag: Serum squamous cell antigen; CA125: OC125 antigen; FIGO: Federation of Gynecology and Obstetrics; VRT: vaginal radical trachelectomy; ART: abdominal radical trachelectomy; LVSI: lymph-vascular space invasion; OS: overall survival; MRI: Magnetic Resonance Imaging; CT: computed tomography; TCT: thin-layer cytology; HPV: Human Papillomavirus; EBRT: external beam radiation therapy

3. Introduction

Cervical cancer is still common malignancy among women worldwide. Following cervical screening popularization, up to 40 % of early stage tumors are diagnosed in reproductive age, and some of them desire childbearing [1]. Fertility-sparing surgery has been an indispensable option for young, childbearing desired patients with early stage cervical cancer. Up to date, various procedures of fertility-sparing surgery for early stage cervical cancer have been reported, such as cone resection, simple trachelectomy, vaginal radical trachelectomy (VRT, Dargent's procedure), abdominal radical trachelectomy (ART), laparoscopic or robotic radical trachelectomy, and fertility-sparing surgery following neoadjuvant chemotherapy [2]. From a pragmatic point of view, the choice among them depends on four major factors: the prognostic factors of the tumor [size, stage, and lymph-vascular space invasion (LVSI) status]; the skill of the gynecological oncologist and the wider team treating the patient; morbidity; and fertility outcomes for the different fertility-sparing procedures [2].

Laparoscopic radical trachelectomy was first described in 2002 [2]. According to a literature review, 260 patients reported in 19 series were underwent full laparoscopic radical trachelectomy, and 138 patients reported in 10 series were underwent robotic radical trachelectomy till 2016 [2]. Laparoscopic surgery has gained worldwide acceptance as a surgical treatment for cancers and presents better perioperative results compared with laparotomic routes, in-

cluding less blood loss and a shorter hospital stay [2-4]. Previous retrospective studies revealed that the safety of laparoscopic radical hysterectomy was equal to that of laparotomic radical hysterectomy in treating cervical cancer [2]. But recently, both prospective and retrospective studies in the *New England Journal of Medicine* showed that the minimally invasive radical hysterectomy was associated with higher recurrence rates and worse overall survival (OS), compared to laparotomic radical hysterectomy in women with stage IA2 or IB1 (Federation of Gynecology and Obstetrics, FIGO 2012) cervical cancer [5-6]. Similarly, the oncological outcomes of laparoscopic fertility-sparing surgery were also uncertain though such a minimally invasive approach had commonly used in clinic, especially in the larger tumors which reduced tumors size to eligible for radical trachelectomy after neoadjuvant chemotherapy, because reported data were limited.

Here, we reported the first case who presented uterine fundus implantation of cervical squamous cell carcinoma, after laparoscopic radical trachelectomy. This special case awakes us to rethink the safety of this fertility-sparing procedure for locally advanced cervical cancer patients.

4. Case Presentation

A 28-year-old nulligravid woman, who was diagnosed as locally advanced squamous cell cervical carcinoma stage IB2 (FIGO 2012) and undergone neoadjuvant chemotherapy followed by laparoscopic radical trachelectomy with pelvic lymphadenectomy 15 months ago, presented with a uterine fundus mass and elevated serum squamous cell antigen (SCC Ag) and OC125 antigen (CA125).

Twenty-six months ago, the patient was admitted to Department of Gynecologic Oncology, Women's Hospital, Zhejiang University School of Medicine, for intermittent and persistent vaginal spotting. The liquid-based Thin-layer Cytology (TCT) Showed Squamous Carcinoma (SCC) and Human Papillomavirus (HPV)16 was positive. Colposcopy revealed a 4.5cm × 3.8cm local cervical mass and biopsy confirmed well differentiated squamous cell carcinoma of the cervix. Magnetic Resonance Imaging (MRI) scanning revealed a 4.5 cm×3.8 cm×3.0 cm cervical mass involving cervix stromal invasion, no parametrial and vaginal infiltration, no lower part of uterus and endometrial involvement, no retroperitoneal lymph node metastasis. After informed-consent, she participated in a clinical trial (NCT02624531) because of strongly desiring to preserve the fertility. She received neoadjuvant chemotherapy with combined paclitaxel 175mg/m² and cisplatin 75mg/m² at three-week intervals. After two cycles, both MRI and colposcopy demonstrated partial response, with a reduction in tumor size to 1.8cm×1.0 cm×2.1cm (Figure 1a-d), then she underwent laparoscopic radical trachelectomy with pelvic lymphadenectomy. Intraoperative the lymph nodes and cervical tissue were bagged and extracted though vagina, after that all lymph nodes and margins

of cervical were confirmed negative by frozen pathological examination. Post-surgical pathology examination revealed well differentiated invasive squamous cell carcinoma, with some histopathological changes such as eosinophilic cytoplasm, vacuolation, and enlarged nuclei (Figure 1e-h). No positive margins, nodal spread, and lymph vascular space involvement were found. After surgery, the patient underwent further four cycles of chemotherapy using the same regimen as that before surgery. However, nine months after treatment ended, the patient was found elevated serum SCC Ag of 2.1 ng/mL (reference, < 1.5 ng/mL) and CA125 of 106 u/mL (reference, <35 u/mL) again. Both human papillomavirus testing and cytology were negative. Colposcopy showed that vagina and cervical os were negative. Two weeks later, serum SCC Ag and CA125 were further elevated to 3.8ng/mL and 223u/mL, respectively. Pelvic transvaginal ultrasound and MRI showed a solitary 4.0 cm×3.5 cm×4.1 cm homogeneous solid mass at the uterine fundus (Figure 2a). Chest and abdomen computed tomography (CT) scans did not show the metastases out of the uterus. The recurrence of cervical carcinoma was considered. One week later, the patient underwent laparoscopic surgery. A 4.0 cm×4.0 cm large, well-demarcated, nonencapsulated tumor with white color was found in uterine fundus (Figure 2b) during laparoscope, the type C radical hysterectomy (RH) and bilateral adnexectomy were performed after the frozen pathological biopsy confirmed recurrence. Final histopathologic examination showed squamous cell carcinoma in uterine fundus (Figure 2c-d), bilateral fallopian tube and ovarian were tumor-free. Three weeks after RH, the patients treated with external beam radiation therapy (EBRT) to a dose of 40Gy. At the time of the manuscript submitting, the patient was alive with disease-free for 17 months.

5. Discussion

The main spread pattern of cervical squamous cell carcinoma is loco-regional invasion, including laterally into the parametrium and distally into the upper vagina, but less often anterior-posteriorly into the bladder or rectum [7]. Spreading to regional pelvic nodes is common, but hematogenous metastases to lungs, liver, brain, etc. is unusual until late in advanced stages of cervical cancer with high grade tumors [8]. Another potential anatomical direction of direct extension in cervical cancer is into the uterine corpus. Retrospective study showed that the uterine corpus tumor invasion is rare in early-stage cervical cancer, especially in squamous histology [8]. A previous study identified 837 (4.9%) cases of uterine corpus invasion in 17074 surgically-treated cervical cancer and found that uterine corpus invasion was independently associated with older age (>50), non-squamous histology, high-grade tumors, large tumor size (>4cm), and nodal metastasis [8]. Non-squamous histology including adenocarcinoma is an independent risk factor for uterine corpus tumor invasion compared to squamous type [8].

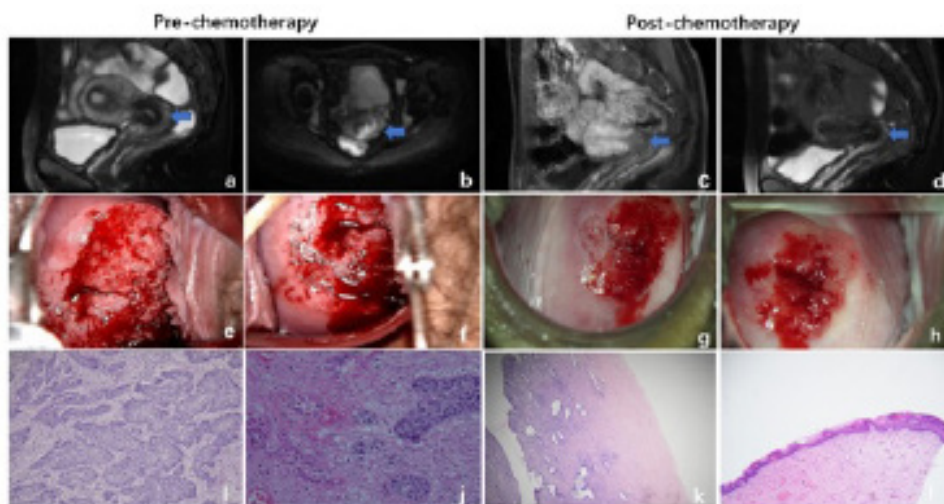


Figure 1: The cervical mass in MRI (arrow) pre- (a, b) and post-chemotherapy (c, d) and colposcopy pre- (e, f) and post-chemotherapy (g, h). Hematoxylin and eosin stain (20× magnification) demonstrating well differentiated invasive squamous cell carcinoma (i, j). Post-surgical pathology indicated the effectiveness of chemotherapy characterized by the presence of eosinophilic cytoplasm, vacuolation, and enlarged nuclei (k, l).

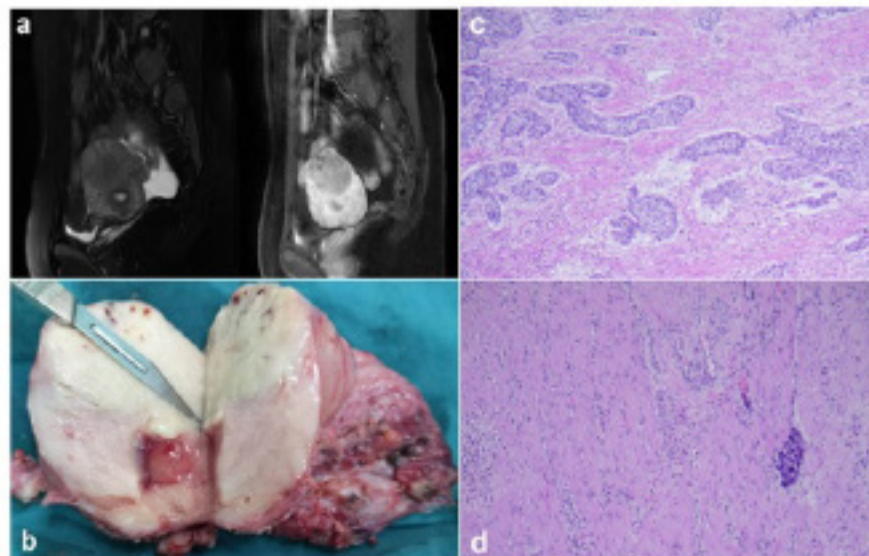


Figure 2: An MRI scan (a) of the uterine and pelvis. An isolated well-demarcated, nonencapsulated tumor in uterine fundus (b). An intramuscular uterine fundus squamous cell carcinoma with vascular infiltration (H&E stain, 20× magnification) (c, d).

The most likely causality of this association is the anatomical proximity to the uterine corpus of the endocervical gland origination of cervical adenocarcinoma. However, cervical squamous carcinoma usually develops at the exocervix and infrequently involves the uterine corpus. Uterine corpus tumor invasion has not been incorporated into the cervical cancer staging system, up to date [8]. Here we reported a case of metastatic uterine corpus cancer that was secondary to a stage IB3 squamous cell cervical cancer. This patient underwent neoadjuvant chemotherapy and laparoscopic radical trachelectomy. She had no surgical-pathological risk factors, but presented a uterine fundus metastasis in a short interval from primary surgery. Pathologic examination confirmed that metastatic squamous carcinoma of uterine fundus was isolated and

did not reach the margin of previous surgery, and endometrium was also not involved, suggesting a very low possibility that the lesion of uterine fundus is a direct extension from original cancer of the cervix. One explanation may be that tumor cells in uterine fundus was carried into by uterine manipulator, which is frequently used for retraction and visualization, during minimally invasive surgery. Furthermore, this implantation metastasis in uterine fundus induced the failure of save fertility ultimately. We had modified the CRF and informed consent of NCT02624531 including not to attempt laparoscopic trachelectomy, till its safety was established.

Radical trachelectomy is typically only for stage IB1 patients with tumor 2cm or less in diameter, negative nodes, and non-aggressive histological subtypes [9]. However, some surgeons proposed that

neoadjuvant chemotherapy could be used for patients with locally advanced stage to reduce tumor size so that fertility was preserved [9]. Platinum-based neoadjuvant chemotherapy has been shown to improve local control (reduce tumor size and parametrial infiltration) and offer a better control of micro metastases in distant sites as well as in regional lymph nodes [10]. In a previous report, totally 25 cervical cancer staging IB3 (FIGO2018) women underwent neoadjuvant chemotherapy plus conservative surgery, including 10 simples vaginal trachelectomy, 10 vaginal radical trachelectomy, and 5 abdominal radical trachelectomy, among them only 2 (8%) recurred [2]. Considering the limitations of retrospective studies, we are conducting a prospective clinical trial (NCT02624531) about the application of fertility-sparing therapy for patients with cervical cancer staging IB1-IIA2 (FIGO2012). According to the protocol, the patient with stage IB3 (FIGO2018) squamous cell cervical carcinoma is assigned to receive two or three cycles of neoadjuvant chemotherapy followed by radical trachelectomy and further three to four cycles of adjuvant chemotherapy after surgery. The patient we reported presented partial remission (PR) to neoadjuvant chemotherapy, which meant that tumor was still existed in the cervix, though the size was reduced, after neoadjuvant chemotherapy. Accordingly, we have reason to speculate that the tumor cells probably moved from cervix and implanted into uterine fundus by uterine manipulator during surgery. Thus, our special case also suggests that it should be considered to avoid the use of uterine manipulator during minimally invasive fertility-sparing surgery or perform abdominal radical trachelectomy instead.

In summary, we reported a special case of uterine fundus implanted cervical squamous cell carcinoma. The patient was diagnosed with stage IB2 (FIGO 2012) and underwent neoadjuvant chemotherapy plus laparoscopic radical trachelectomy. Pathologic diagnosis was well-differentiated squamous cell carcinoma without pathologic risk factors. The patient suffered from metastatic cancer in uterine fundus later and underwent radical surgery finally. This case with special metastatic manner indicates that the safety of laparoscopic radical trachelectomy is still uncertain for advanced stage cervical cancer even if neoadjuvant and post-surgery chemotherapy is given, and also suggests that it is needed to discuss carefully the benefit and risk of such a strategy with the patient when the fertility preservation is considered.

6. Declarations

- **Ethics approval and consent to participate:** This research conformed to the provisions of the Declaration of Helsinki. The patient was informed and provided her written informed consent. This study was approved by the ethics committee of Women's hospital Zhejiang University
- **Consent for publication:** The patient was informed and provided her written informed consent.

- **Availability of data and materials:** The datasets used and analyzed during the current study are available from the corresponding author on reasonable request
- **Competing interests:** we certify that no actual or potential conflict of interest in relation to this article exists. We also certify that non-financial competing interests include political, personal, religious, ideological, academic, and intellectual competing interests.
- **Funding:** Natural Science Foundation of Zhejiang province China NO.LY19H160043. The role the funding is to supported the clinical trial (NCT02624531).
- **Authors' contributions:** Yuanming Shen and Xie Xing made substantial contributions to the conception. Jihong Liu and Xie Xing design of the work; Yuanming Shen and Xiaoyun Wan interpretation of data; Yuanming Shen have drafted the work; Jihong Liu and Xie Xing substantively revised it.
- **Acknowledgements:** Thank you for Dong Xiao Hu who provided only general support.

Reference

1. Bray F, Ferlay J, Soerjomataram I, Siegel RL, Torre LA, Jemal A. Global cancer statistics 2018: GLOBOCAN estimates of incidence and mortality worldwide for 36 cancers in 185 countries. *CA Cancer J Clin.* 2018; 68(6): 394-424.
2. Bentivegna E, Gouy S, Maulard A, Chargari C, Leary A, Morice P. Oncological outcomes after fertility-sparing surgery for cervical cancer: a systematic review. *Lancet Oncol.* 2016; 17(6): e240-53.
3. Diver E, Hinchcliff E, Gockley A, Melamed A, Contrino L, Feldman S, et al. Minimally invasive radical hysterectomy for cervical cancer is associated with reduced morbidity and similar survival outcomes compared with laparotomy. *J Minim Invasive Gynecol.* 2017; 24 (3): 402-6.
4. Rizou N, Moris D, Pikoulis E, Dimitrokallos N, Mpaili E, Felekouras E, Papalampros A. Minimally invasive lymphadenectomy in uterine cervical cancer a systematic review. *Anticancer Res.* 2017; 37(1): 335-42.
5. Ramirez PT, Frumovitz M, Pareja R, Lopez A, Vieira M, Ribeiro R, et al. Minimally invasive versus abdominal radical hysterectomy for cervical cancer. *N Engl J Med.* 2018; 379(20): 1895-904.
6. Melamed A, Margul DJ, Chen L, Keating NL, Del Carmen MG, Yang J, et al. A Survival after minimally invasive radical hysterectomy for early-stage cervical cancer. *N Engl J Med.* 2018; 379(20): 1905-14.
7. Barakat RR, Markman M, Randall ME, editors. *Principal and practice of gynecologic oncology.* 5th ed. Philadelphia: Lippincott Williams & Wilkins; New York. 2009; pp623-81.
8. Matsuo K, Machida H, Blake EA, Takiuchi T, Mikami M, Roman LD. Significance of uterine corpus tumor invasion in early-stage cervical cancer. *Eur J Surg Oncol.* 2017; 43(4): 725-34.

9. Marchiole P, Tigaud JD, Costantini S, Mammoliti S, Buenerd A, Moran E, et al. Neoadjuvant chemotherapy and vaginal radical trachelectomy for fertility-sparing treatment in women affected by cervical cancer (FIGO stage IB-IIA1). *Gynecol Oncol.* 2011; 122: 484-90.
10. Robova H, Halaska MJ, Pluta M, Skapa P, Matecha J, Lisy J, Rob L. Oncological and pregnancy outcomes after high-dose density neoadjuvant chemotherapy and fertility-sparing surgery in cervical cancer. *Gynecol Oncol.* 2014; 135: 213-6.